

## SECTION IV. AUTHENTICITY

### PART I. INTRODUCTION

(151) At the outset of the investigation into the issues concerning the medical evidence, the committee determined that experts should examine the autopsy photographs and X-rays for two purposes: First, to establish or repudiate their authenticity (whether they are photographs and X-rays taken of President Kennedy at the time of his autopsy); and second, to determine whether anyone altered or "doctored" them. Such examinations were essential to the analysis of consultants whom the committee charged with interpreting the medical evidence, since their conclusions were to be based principally on the evidence derived from the autopsy photographs and X-rays.

(152) The committee also wanted these examinations conducted as one way to resolve the varying accounts of where the wounds to the President were situated. If the photographs and X-rays were proven to be authentic and unaltered, then any account of the President's wounds which differed from what they showed would be incorrect. Conversely, if the photographs or X-rays or both were proven to be fake or altered, they might then provide a clue which would assist in determining which account of the injuries was correct.

(153) The various accounts of the nature of the wounds to the President differ significantly. As revealed in section 2 of this volume, "Performance of the Autopsy," eyewitness descriptions of the wounds, as described by staff at Parkland Memorial Hospital, differed from those in the autopsy report, as well as from what appears in the autopsy photographs and X-rays.(1) Further, the reports of FBI agents Sibert and O'Neill referred to "surgery" of the head area being evident when the body arrived for the autopsy,(2) yet no surgery of the head area was known to have been performed. Finally, the Clark panel—the panel of experts assembled in 1968 by then-Acting Attorney General Ramsey Clark—said the entrance wound in the President's head was 10 centimeters (almost 4 inches) higher than was described by the autopsy pathologists.(3)

(154) Critics of the Warren Commission's medical evidence findings have found on the observations recorded by the Parkland Hospital doctors.(4) They believe it is unlikely that trained medical personnel could be so consistently in error regarding the nature of the wounds, even though their recollections were not based on careful examinations of the wounds.

(155) In disagreement with the observations of the Parkland doctors are the 26 people present at the autopsy. All of those interviewed who attended the autopsy corroborated the general location of the wounds as depicted in the photographs; none had differing accounts.(5) Further, in 1967 the autopsy pathologists, Drs. Humes, Boswell, and Finck, as well as Dr. James H. Ebersole, the acting chief

of radiology, and one of the autopsy photographers, John Thomas Stringer, viewed the autopsy photographs or X-rays, or both, and verified them as accurately portraying the wounds of President Kennedy.(6)

(156) Aside from using scientific analysis to determine authenticity and verify that no alterations had been made, the committee also considered what reasonably might have happened. It assumed that if the Parkland doctors are correct, particularly with respect to the gaping hole in the back of the President's head, then it would mean: (1) The autopsy photographs and X-rays had been doctored to conceal this hole; (2) the body itself had been altered, either before its arrival at Bethesda or during the autopsy so that the hole was not obvious in the photographs and X-rays; or (3) the photographs and X-rays were not of President Kennedy. Further, if the Parkland doctors are correct, then the autopsy personnel are incorrect and either lying or mistaken.

(157) It did not seem plausible to the committee that 26 persons would be lying or, if they were, that they could provide such a consistent account of the wounds almost 15 years later. Second, it is less likely that the autopsy personnel would be mistaken in their general observations, given their detailed and thorough examination of the body. Consequently, it seems reasonable to assume that the autopsy personnel were correct.

(158) If the autopsy doctors are correct, then the Parkland doctors are incorrect and either lying or mistaken. It does not seem probable that they are lying, because it would be difficult to maintain a conspiracy of lying among the approximately 14 persons involved for 15 years. On the other hand, it does seem possible, that the Parkland personnel could be mistaken, given their cursory observations of the wounds, the brief period of time they examined the President, and their function at the time: To administer emergency procedures to save the life of the President, rather than to document the nature and location of his wounds.

(159) The theoretical possibility also exists that both Parkland and the autopsy personnel are correct in their observations and that the autopsy photographs and X-rays accurately reflect the observations of the autopsy personnel. This could have occurred if someone had altered the body while in transit from Parkland Memorial Hospital to Bethesda Naval Hospital. This possibility however, is highly unlikely or even impossible. Secret Service agents maintained constant vigilance over the body from Parkland to Bethesda and stated that no one alter the body.(7) Second, if such alterations did occur, it seems likely that the people present at the autopsy would have noticed them; in which case they are now lying about their observations. As stated previously, this does not appear likely.

(160) A further complicating factor could be the possibility that all persons are somewhat mistaken in their observations or their memories of them and that the autopsy photographs and X-rays do not portray the wounds in sufficient detail to resolve the matter. This possibility would not, however, account for the major disagreement between the Parkland and autopsy personnel: A large, gaping wound in the rear of the head.

(161) Consequently, without considering any scientific analysis to evaluate authenticity and any possibility of the autopsy photographs and X-rays having been altered, it appears more probable that the observations of the Parkland doctors are incorrect.

## PART II. PROCEDURES EMPLOYED IN EXAMINING THE AUTOPSY PHOTOGRAPHS AND X-RAYS

(162) As mentioned, the committee did, however, subject the autopsy photographs and X-rays to scientific analysis. These examinations by the committee's consultants established the inaccuracy of the Parkland observations. The experts concluded that the autopsy photographs and X-rays were authentic and unaltered, confirming the observations of the autopsy personnel and providing additional support for the conclusions of the medical consultants.

(163) From the beginning, the committee's investigative approach in the medical evidence area was to assume nothing about the authenticity of the photographs and X-rays. To conduct the analyses to determine whether the photographs and X-rays could be identified as being of the President and whether they were altered, the committee retained experts in the following areas: Anthropology, forensic dentistry, photographic interpretation, forensic pathology, and radiology.

(164) Anthropologists studied the autopsy photographs in an attempt to verify the consistency of the subject matter, specifically, whether the photographs of the rear of the head could be identified as being consistent with photographs of other views of the head in which the President's facial features are recognizable. The anthropologists determined that the posterior photographic views of the head are identifiable as part of the same head as is visible in the side or front views and hence concluded that the posterior views are photographs of President Kennedy. (8)

(165) The anthropologists also studied the autopsy X-rays in comparison with premortem X-rays of President Kennedy, obtained from the Kennedy Library in Waltham, Mass. (9) The premortem X-rays had been collected by the Library from a number of different sources (10) over a period of a couple of years. (11)

(166) By studying the premortem X-rays, the anthropologists were able to observe a number of unique anatomic characteristics whose absence or presence among the autopsy X-rays would, in their opinion, be determinative of whether the two sets of X-rays were of the same person. (12) Some of the anatomic characteristics they noted included: turcica, cranial sutures, vascular grooves and the air cells of the mastoid bone. (13) The anthropologists were able to observe enough of these anatomical features among the autopsy X-rays to conclude that the autopsy and premortem X-rays were taken of the same individual. (14)

(167) The committee also retained an expert in dental comparison, Dr. Lowell Levine, a forensic odontologist (15) experienced in the identification of victims of unnatural death, including, for example, individuals killed in airplane crashes. Dr. Levine also compared premortem X-rays with the autopsy X-rays. He was confident in his conclusion that the three autopsy skull X-rays are identifiable as being

of the same person as the premortem dental X-rays of President Kennedy. (16) Dr. Levine presented his conclusions in his public testimony before the committee on September 7, 1978.

(168) Once it was determined that the autopsy photographs and X-rays were of the President, the committee used relevant scientific expertise to look for evidence of alteration. Different techniques were used for studying the photographs and X-rays.

(169) Members of the committee's photographic panel carefully studied the autopsy photographs, negatives and transparencies. (17) There were a number of features the panel members noticed that were relevant to the issue of authenticity, including: emulsion numbers on the films, a pentagonal shaped light spot, and a number of sets of photographic stereo pairs. (18)

(170) On April 8, 1978, David Eisendrath contacted Kodak to determine what information, if any, could be gleaned from the numbers visible on the autopsy films. (19) David Greenlaw responded for Kodak on June 8, 1978, providing information that indicated the numbers matched emulsion batches produced in 1963 and, in one film type, an operator number which was discontinued in 1969. (20)

(171) Several stereo pairs which the panel observed among the autopsy photographs were suitable for stereoscopic viewing. A stereo pair is created when the photographer takes two pictures of a particular scene with either the camera or the object in slightly different position. According to Scott, (21)

A pair of stereo pairs enables one to see the scene in three-dimensions; stereo pictures add depth to the perception of the photographed scene in much the same way as a pair of human eyes, separated from one another in space, can perceive depth.

(172) Also according to Scott, stereoscopic viewing heightens the ability of the human eye to perceive differences between the two photographs of a stereo pair:

To successfully avoid detection of picture alteration requires that each picture of a pair of pictures be altered identically, which is essentially impossible, particularly with a stereo pair \* \* \* Any nonidentical alteration of the pictures of a pair is readily noted when pairs are viewed stereoscopically or microscopically. (22)

(173) Fortunately, the autopsy photographer had taken two or more pictures of each scene, some of which were stereo pairs because of slight differences. (23)

(174) Scott believed there were pairs of autopsy photographs that provided sufficient stereoscopic viewing quality to permit the conclusion of authenticity, including: The back of the head (Nos. 42 and 43), top of the head (Nos. 32 and 33, and Nos. 34 and 37); the large skull defect (Nos. 44 and 45), and the head from the front right (Nos. 26 and 28). (24)

(175) Scott said that in these he " \* \* \* did not find any indication or evidence that any of the pictures were altered \* \* \*" and thus concluded that the photographs for which there were stereo pairs " \* \* \* are authentic photographs." (25)

(176) Calvin McCamy, a photogrammetrist, testified in public session of the select committee on September 7, 1978, on behalf of the photographic evidence panel on the issue of the authenticity of autopsy photographs. He agreed with Scott's assessment of the authenticity of the stereophotographic views and added that in his analysis, he found additional stereo pairs permitting the additional conclusions that the photographs of the back wound (Nos. 38 and 39) and of the anterior neck wound (Nos. 40 and 41) are authentic. (26)

(177) Dr. Gerald McDonnel examined the premortem and post-mortem X-rays for evidence of alteration. (27) He reported that an alteration of the images " \* \* \* should be readily \* \* \*" discernible in a number of ways:

- a. Observation of a difference in density of the images,
- b. Discontinuity of anatomical structures,
- c. Alteration of continuity of an abnormal pattern, or
- d. Production of an image which is not anatomical or an image of an impossible pathologic process. (28)

(178) Dr. McDonnel concluded that "[t]he radiologic images both ante mortem and post mortem, have not been altered in any fashion \* \* \*" except for two small areas of thermal damage and "minor \* \* \* discoloration of the images due to incomplete processing of the film \* \* \*" Neither of these conditions affected the conclusion that the images were not altered " \* \* \* to provide a false image \* \* \*" nor " \* \* \* to produce misinformation and therefore improper conclusions." (29)

For further explanation of the authenticity of the autopsy photographs and X-rays, see paragraphs 512-604 of the Report of the Photographic Evidence Panel.

### PART III. CONCLUSIONS

(179) From the reports of the experts' analyses of the autopsy photographs and X-rays, the evidence indicates that the autopsy photographs and X-rays were taken of President Kennedy at the time of his autopsy and that they had not been altered in any manner.

### REFERENCES

(1) See sec. II of this volume, "Performance of the Autopsy, part II, Facts and Issues," para. 34 ff.

(2) FBI Report, BA 89-30, Nov. 26, 1963, p. 3 (JFK Doc. No. 013618).

(3) Report pursuant to a request by Hon. Ramsey Clark, Attorney General of the United States, entitled "1968 Panel Review of Photographs, X-ray films, Documents, and Other Evidence Pertaining to the Fatal Wounding of President John F. Kennedy on November 22, 1963, in Dallas, Tex.," April 1968.

(4) Sylvia Meagher, "Accessories After the Fact" (New York: Random House, Inc., 1976), pp. 134-165; Josiah Thompson, "Six Seconds in Dallas" (New York: Berkley Publishing Corp., 1976), pp. 131-151.

(5) Staff interviews with persons present at the autopsy, House Select Committee on Assassinations. For citations to these reports, see generally sec. II of this volume, "Performance of the Autopsy," paras. 42-94.

(6) Blank letterhead memorandum, Jan. 26, 1967, from James J. Humes, M.D., J. Thornton Boswell, M.D., pursuant to a Department of Justice request to examine the autopsy photographs and X-rays; blank letterhead memorandum entitled, "Report of Inspection by Naval Medical Staff on November 1, 1966, at National Archives of X-Rays and Photographs of Autopsy of President John F. Kennedy," signed James J. Humes, M.D., J. Thornton Boswell, M.D., John H. Ebersole, M.D., and John T. Stringer, Nov. 10, 1966.

(7) Outside contact report, William Greer, Dec. 4, 1978, House Select Committee on Assassinations (JFK Doc. No. 014880); Outside contact report, Roy H. Kellerman, Dec. 1, 1978 (JFK Doc. No. 013394).

(8) John F. Kennedy Autopsy Authentication, a report to the House Select Committee on Assassinations by Ellis R. Kerley, Ph. D., and Clyde C. Snow, Ph. D., Feb. 9, 1979, pp. 1-2.

(9) Authentication of John F. Kennedy Autopsy Radiographs and Photographs, a report to the Select Committee on Assassinations, U.S. House of Representatives, by Ellis R. Kerley, Ph. D., and Clyde C. Snow, Ph. D., Feb. 28, 1979, p. 1, Lowell J. Levine, D.D.S., "Identification of the Skull X-ray Films Taken During the Autopsy of President John F. Kennedy." Sept. 7, 1978, p. 5. Levine's report is contained in volume I, pp. 153-176, of the hearings before the House Select Committee on Assassinations, 95th Cong., 2d sess. (Washington, D.C.: U.S. Government Printing Office, 1979).

(10) Some of the premortem dental films were supposed to have been taken by Robert D. Morris, D.D.S., 140 East 54th St., New York, N.Y. In a telephone interview between Dr. Levine and Dr. Morris, Dr. Morris confirmed that he had taken X-rays of the President on the date indicated on the X-ray films. See reference 9, Levine report, pp. 9, 16.

(11) *Id.* at p. 5.

(12) See reference 8, Kerley and Snow report, pp. 1-2.

(13) *Id.* at pp. 2-4.

(14) *Id.* at p. 4.

(15) See reference 9, Levine report, pp. 1-4, for a discussion and description of the function of a forensic odontologist (dentist).

(16) *Id.* at p. 20.

(17) Letter from Frank Scott to House Select Committee on Assassinations, Aug. 15, 1978. Testimony of Calvin S. McCamy, Sept. 7, 1978, Hearings Before the Select Committee on Assassinations, U.S. House of Representatives, 95th Cong., 2d sess. (Washington, D.C.: U.S. Government Printing Office, 1979), vol. I, p. 176 (hereinafter referred to as McCamy testimony, Sept. 7, 1978, I HSCA-JFK hearings, 176).

(18) Letter to Michael Goldsmith, from David B. Eisendrath, June 10, 1978, House Select Committee on Assassinations (JFK Doc. 009129); letter to Jane Downey from David B. Eisendrath, Oct. 23, 1978, House Select Committee on Assassinations, (JFK Doc. No. 012845); see reference 17, McCamy testimony, Sept. 7, 1978, I HSCA-JFK hearings, 176.

(19) Letter from David B. Eisendrath, to David S. Greenlaw, director, Corporate Commercial Affairs Eastman Kodak Co., Apr. 8, 1978, House Select Committee on Assassinations (JFK Doc. No. 012845).

(20) Letter from David S. Greenlaw, assistant vice president, Corporate Commercial Affairs, Eastman Kodak Co., to David B. Eisendrath, June 8, 1978, House Select Committee on Assassinations (JFK Doc. No. 009129).

(21) Letter to Jane Downey from Frank Scott, Aug. 15, 1978, House Select Committee on Assassinations p. 1.

(22) *Id.* at p. 2.

(23) *Id.* at p. 1.

(24) *Id.* at p. 4.

(25) *Id.* at p. 3.

(26) McCamy testimony, Sept. 7, 1978, I HSCA-JFK hearings. pp. 176-179.

(27) Report of G. M. McDonnell, M.D., concerning observation, analysis, and conclusions in connection with radiographic images and enhanced images attributed to President John F. Kennedy. Aug. 4, 1978. See addendum C of the Forensic Pathology Panel Report (sec. V of this volume) for this document.

(28) Report of G. M. McDonnell, M.D., Mar. 8, 1978, p. 4. See addendum C of the Forensic Pathology Report (sec. V of this volume) for this document.

(29) *Ibid.*

(180) ADDENDUM A

AUTHENTICATION OF JOHN F. KENNEDY AUTOPSY RADIOGRAPHS AND  
PHOTOGRAPHS

Final Report to the Select Committee on Assassinations, U.S. House  
of Representatives—March 9, 1979

Ellis R. Kerley, Ph. D.<sup>1</sup>  
Clyde C. Snow, Ph. D.<sup>2</sup>

BOARD OF ANTHROPOLOGY CONSULTANTS, PHOTOGRAPHIC PANEL,  
HOUSE SELECT COMMITTEE ON ASSASSINATIONS

Various conspiracy theorists have questioned the authenticity of the post mortem radiographs and photographs taken during the autopsy of President John F. Kennedy at the U.S. Naval Hospital on November 22, 1963. The anthropology consultants were asked by the committee to examine these materials and, if scientifically possible, determine whether or not they were indeed those of the late President. Our approach to this problem was through the comparison of the post mortem X-rays and photographs with those known to have been taken prior to his death.

AUTHENTICATION OF X-RAYS

*Introduction*

It is a well-established fact that human bone structure varies uniquely from one individual to another. The bones not only differ in their overall size and shape, but also in their minute structural details so that the total pattern of skeletal architecture of a given person is as unique as his or her fingerprints. Forensic anthropologists have long made use of this fact in establishing the positive identification of persons killed in combat, aircraft accidents, or other disasters, by comparing X-rays taken before death with those of the unidentified body taken after death.

Of course, just as no two individuals are alike, no two X-rays of the same bones of the same person are ever exactly alike because there is always some variation in the positioning of the subject, the X-ray technique, and the processing of the film. The skeleton also undergoes some remodeling throughout life, so that a certain amount of variation in detail is to be expected in films of the same individual taken a few years apart. However, with experience, these technical and age variations can be taken into account so that, given a pair of reasonably good films of the same person, posed in the same way, a positive identification can nearly always be made even if the X-rays were made many years apart by different technicians using different equipment.

<sup>1</sup> Department of Anthropology, University of Maryland, College Park, Md.

<sup>2</sup> Civil Aeromedical Institute, Mike Monroney Aeronautical Center, Federal Aviation Administration, Oklahoma City, Okla.

In the following analysis we have applied this method in comparing the post mortem X-rays said to be those of President Kennedy with clinical films known to have been taken prior to his death.

### *Materials examined*

Both ante mortem and post mortem X-rays were examined were from the JFK assassination materials created by the U.S. National Archives in Washington, D.C.

The autopsy X-rays bear the case No. 21296 of the U.S. Naval Hospital in Bethesda, Md. They include front and side views of the skull as well as a series of overlapping views of the torso and upper legs. There are also several X-rays of three skull fragments reportedly found in the Presidential automobile after the assassination.

In addition to the autopsy X-rays, the Archives collection includes three sets of clinical X-rays of President Kennedy taken at various times prior to his death. Two of these sets were made by personal physicians who treated the then-Senator Kennedy for an upper respiratory illness in August 1960. The earliest, dated August 14, bears the case No. 202617 of Dr. Stephen White, 521 Park Avenue, New York. The second set was made 3 days later at the clinic of Drs. Groover, Christie, and Merritt, of 1835 I Street NW., Washington, D.C., and bears the case number 336042. Dr. White's series consists of a side view of the head and a routine chest plate. Those from the Groover, Christie, and Merritt Clinic, include side and front views of the skull. The third set of ante mortem X-rays were taken at the U.S. Naval Hospital in Bethesda on March 14, 1962, while President Kennedy was undergoing treatment for a back complaint. These X-rays consist of front and side views of the lower spine and pelvis. Hereafter these three sets of ante mortem X-rays will be referred to as the "White," "Groover," and "Navy" films, respectively.

We first compared the "Groover" and "White" ante mortem X-rays of the skull with the autopsy films.

In the front views, we found that the outlines of the frontal sinuses of the autopsy X-rays were virtually superimposable on those shown in the clinical X-rays. The sinuses, which are lobular air pockets inside the bone that forms the forehead, vary uniquely in size and shape from one person to another. This variability is seen particularly in the outlines of their upper margin which typically cast a set of scallop-like shadows on the X-ray. This scallop pattern is so individually distinctive that forensic anthropologists have termed them "sinus prints." For many years, law courts throughout the world have accepted the matching of ante mortem and post mortem X-rays of the sinuses as evidence for the positive identification of unknown bodies. In the present case, the similarity in shape of the sinus print patterns in the ante mortem and post mortem films is sufficient to establish that they are of the same person on the basis of this trait alone.

In addition to the sinus prints, several other strikingly similar anatomical features were observed in the front view X-rays. For example, the nasal septum—the thin wall of cartilage and bone that separates the nostrils—was deviated to the same side and to an identical degree in ante mortem and post mortem films. Also the outlines of the bony rims of the orbits of the eyes were nearly identical. The very slight variations observed in these three features—sinus pattern, nasal



septum, and orbital margins—are the result of minor differences in the way the X-rays were taken.

The profile views of the skull in the White and Groover films were next compared to the autopsy X-rays. Again, a number of almost identical anatomical features were observed in the ante mortem and post mortem films. For example, the outlines of the *sella turcica* (the saddleshaped depression in the base of the skull), the complex patterns of the cranial sutures (the joints uniting the bones of the skull), and location and arrangement of the vascular grooves (the shallow depressions on the inner surface of the skull which mark the course of blood vessels), were the same. There was also nearly exact duplication of the honeycomb-like air cells of the mastoid bone.

The chest X-ray taken by Dr. White in 1960, was next compared to those of the upper torso taken at autopsy. Again, a number of identical features were noted in both sets of films. Among these were the outlines of the dorsal spines of the thoracic vertebrae. (These spines are the bony projections that are visible just under the skin along the center of the back.) In X-rays these spines project a vertical series of small shadows of varying sizes and shape that, like the architectural features of the skull discussed above, are virtually unique in each individual. In shape these shadows may range from almost perfect circles to irregular trapezoids. They vary not only from one individual to the next, but from one vertebra to another in the same individual so that the series of a dozen or so of these spines usually visible in a standard chest film, form a combination of shapes distinctive for each individual. Allowing for slight distortions due to position and technique, this series of spines can be considered identical in the ante-mortem and postmortem films.

In addition to the similar pattern of dorsal vertebrae spines, a number of other features common to both sets of films were observed. For example, the size and shape of the medial ends of the clavica (collar bones) were identical, as was the pattern of ossification of the costochondral junctions of the first ribs. Numerous details in the form and trabecular structure of the ribs could also be matched from one set of films to the other, particularly in the left eighth and ninth ribs which were especially well-defined in both films.

The autopsy radiographs of the lower torso, including the pelvis and upper legs, could be compared to the ante mortem "Navy" films taken in 1962. These also show an impressive number of osseous details in common. Of particular interest was the right transverse process of the fifth lumbar vertebra. In both sets of films it was displaced upward in a manner suggestive of a congenital malformation or an old, un-united fracture.

To summarize, the skull and torso radiographs taken at autopsy match the available ante mortem films of the late President in such a wealth of intricate morphological detail that there can be no reasonable doubt but that they are indeed X-rays of John F. Kennedy and no other person.

#### AUTHENTICATION OF AUTOPSY PHOTOGRAPHS

##### *The issue*

Among the JFK assassination materials in the National Archives is a series of negatives and prints of photographs taken during autopsy. The deficiencies of these photographs as scientific documentation of a

forensic autopsy have been described elsewhere (Wilbur, 1968). Here it is sufficient to note that :

1. They are generally of rather poor photographic quality.
2. Some, particularly closeups, were taken in such a manner that it is nearly impossible to anatomically orient the direction of view.
3. In many, scalar references are entirely lacking, or when present, were positioned in such a manner to make it difficult or impossible to obtain accurate measurements of critical features (such as the wound in the upper back) from anatomical landmarks.
4. None of the photographs contain information identifying the victim; such as his name, the autopsy case number, the date and place of the examination.

In the main, these shortcomings bespeak of haste, inexperience and unfamiliarity with the understandably rigorous standards generally expected in photographs to be used as scientific evidence. In fact, under ordinary circumstances, the defense could raise some reasonable and, perhaps, sustainable objections to an attempt to introduce such poorly made and documented photographs as evidence in a murder trial. Furthermore, even the prosecution might have second thoughts about using certain of these photographs since they are more confusing than informative. Unfortunately, however, they are the only photographic record of the autopsy.

Not all the critics of the Warren Commission have been content to point out the obvious deficiencies of the autopsy photographs as scientific evidence. Some have questioned their very authenticity. These theorists suggest that the body shown in at least some of the photographs is not President Kennedy, but another decedent deliberately mutilated to simulate a pattern of wounds supportive of the Warren Commission's interpretation of their nature and significance. As outlandish as such a macabre proposition might appear, it is one that, had the case gone to trial, might have been effectively raised by an astute defense anxious to block the introduction of the photographs as evidence. In any event, the onus of establishing the authenticity of these photographs would have rested with the prosecution.

With the above considerations in mind, HSCA requested the anthropology consultants to examine the questions surrounding the authenticity of the JFK autopsy photographs. It should be emphasized that our inquiry was limited to determining the identification of the victim shown in the photographs. Other aspects of authentication concerning the possibility of technical alterations of the negatives and prints fall within the purview of other photographic experts. Also, we did not concern ourselves with the description and location of the wounds or of their nature and significance, since this was clearly the responsibility of the forensic pathology consultants.

#### MATERIALS EXAMINED

##### *Post mortem*

According to inventories (Humes et al., 1966, Carnes et al., 1968) of the JFK autopsy materials in the National Archives, the collection includes a total of 52 exposed negatives. These may be divided into two series: (1) 25 4 by 5 inch black and white, and (2) 27 4 by 5 inch color negatives. The entire series is numbered sequentially beginning

with the black-and-white series: Black and white; No. 1 to No. 25; color; No. 26 to No. 52.

Examination of prints of the total series revealed that most of the black-and-white negatives are virtually duplicates, in subject and view, to corresponding negatives in the color series. Therefore, our detailed analysis was limited to an examination of the latter. These items were in the form of 8 by 10-inch enhanced prints especially prepared for HSCA by Kodak Laboratories. Each print was identified by its original negative number. The entire series is described by subject in table I.

#### *Ante mortem*

In order to compare the facial features of the autopsy subject with John F. Kennedy, a number of ante mortem photographs of President Kennedy were examined. These were also furnished by the National Archives. Two of these (National Archives Accession Nos. 79-AR-6378G and 79-AR-8008K) were selected for a more detailed comparison since they show a full profile of the subject with his mouth slightly open, and in pose and camera angle, correspond almost exactly with the full profile view of autopsy photograph No. 29.

#### *Analysis*

To examine the autopsy photographs from the standpoint of identification of the victim we have considered two hypotheses:

1. That the subject shown in the photographs was not John F. Kennedy, but an unknown victim with a strong resemblance to the assassinated President.
2. That the victim in the photographs, in which the facial features are clearly visible, is indeed John F. Kennedy, but the body in which the face is not shown (particularly photographs No. 32 thru No. 37 which document the location of the critical wounds of the back and head) is that of another, unknown, individual.

In order to test the first hypothesis, it was necessary to compare the facial features of the victim in the autopsy photographs with ante-mortem photographs of President Kennedy. This comparison was made on the basis of both metric and morphological features.

In making this comparison, it was first noted that there were no gross inconsistencies between the autopsy victim and general physical characteristics of John F. Kennedy. The victim is a well-nourished, dark-haired, middle-aged, white male who appears to be of northern European ethnic stock.

Our metric analysis was based on a comparison of autopsy photograph No. 29 with the two ante mortem photographs (79-AR-6378G and 79-AR-8008K) selected from the National Archives series. The exact date of the ante mortem photographs was not determined, but both were made during the Kennedy Presidency and, therefore, do not antedate the autopsy photograph by more than 3 years. All three photographs show the subject in nearly perfect facial profile; Autopsy No. 29 and 79-AR-8008K are left profile and 79-AR-6378G is a right profile photograph.

A series of 11 facial measurements were taken on each photograph. These measurements are defined in table II. Measurements were recorded to the nearest 1 mm and made from 8 by 10-inch prints.

Three sets of measurements were made on each photograph, and the means were used to calculate the 10 indices given in table III. The arrangement of President Kennedy's hair made it impossible to take Physiognomic Face Height (No. 1) in photographs 79-AR-6378G; otherwise, all the 11 measurements could be taken on each photograph.

As shown in table III, the index values of the autopsy photograph and the two ante mortem photographs correspond very closely. For further comparison, the mean of the ante mortem indices was compared with the post mortem values (represented by a single value in indices 1, 4, and 7 which as based on measurement No. 1 that could not be taken on 79-AR-6378G). The deviation between the ante mortem and post mortem means range from 0.3 to 4 and the average deviation is 2.82 (table III). This small deviation can be accounted for by a combination of several factors such as the fact that in the autopsy the subject is supine while he is standing erect in the ante mortem photographs, and gravitational effects would cause some alteration of the facial features. The facial measurements would also be influenced by post mortem alterations and the effects of the massive cranial trauma. In short, the metric similarities, as expressed by facial indices are insignificant.

In addition to the strong metric similarities between autopsy photograph No. 29 and the two ante mortem photographs, a number of identical morphological features can be observed. Our examination of morphological similarities was not limited to the three photographs from which the measurements were taken, but included comparisons between the other autopsy photographs which show the victim's face (Nos. 26, 27, 28, 29, 30, 31, 40, and 41) and a series of 43 close-up photographs of President Kennedy selected from National Archives files to show his head and face from a variety of angles. In these comparisons, no inconsistencies in the morphological configuration of the eyes, nose, mouth, ears, or other facial features were observed and, on the contrary, a number of identical features were apparent. These include rather distinctive traits such as the downward convexity of the nasal septum and an angular and elevated nasal tip (the latter, by the way, a trait observable in other members of the Kennedy family). Among similarities noted in the ears are a strong antihelix, small, "tucked" tragus, narrow intertragic notch and attached lobes. The lower margin of the helix is strongly concave at its junction with the lobe, giving the latter a rather attenuated appearance. Patterns of facial lines and wrinkles were similar where they could be visualized in autopsy photographs. A partial list of morphological similarities between the autopsy subject and President Kennedy are shown in table IV. While they are simply listed in the table, each has a distinctiveness about it that impressed the examining anthropologists, both of whom have examined similar traits in a large number of human faces. Each of these traits, of course, can be separately observed in the general population. However, the probability of their occurring together in a single person is small. Their occurrence in two individuals with near-identical facial proportions, as expressed by the indices, is extremely remote.

On the basis of the foregoing, we conclude that the individual shown

in the autopsy photographs which show the victim's face is beyond reasonable doubt, President John F. Kennedy.

If it is accepted that the autopsy photographs showing the victim's face are those of John F. Kennedy, it then is necessary to examine the second hypothesis—namely that the remaining autopsy photographs are those of another person.

Examination of table I shows that the entire series of 27 autopsy photographs can be grouped as follows:

Groups:	Negative Nos.
1. Left lateral views-----	29, 30, 31
2. Right lateral views-----	26, 27, 28, 40, 41
3. Superior views-----	38, 39, 42, 43
4. Posterior views-----	32, 33, 34, 35, 36, 37
5. Cranial cavity-----	44, 45
6. Brain-----	46, 47, 48, 49, 50, 51, 52

The photographs within each of the groups vary only slightly in camera angle, lens-subject distance, subject position, lighting and exposure. There is also sufficient commonality in morphological features and other details to leave no doubt but what they are of the same subject. Since we have concluded that photographs in groups 1 and 2 (showing the face) are those of President Kennedy, we can compare these with features observed in the other photographs.

From the standpoint of pathological interpretation, the least informative photographs are those of group 3, which provide a superior view of the head and shoulders. This is because the scalp has neither been shaved or reflected from the cranium, procedures which would possibly have shown some of the crucial details of the cranial trauma. In these photographs, a portion of the victim's forehead and nose are shown from above. The configuration of these facial features are consistent with the nose and upper forehead contours of President Kennedy as surmised from the ante mortem photographs taken from more conventional angles. Also, certain random features such as blood-stains and an apparent post mortem, abrasion on the right shoulder (described in more detail below), which can be seen in the photographs of group 2, can be observed in this set of photographs. We are therefore of the opinion that these photographs are of the same person as shown in groups 1 and 2 of the autopsy photographs—namely, John F. Kennedy.

The most critical set of photographs from the standpoint of identification are those of group 4 that show the head and upper back of the victim from behind. To take these photographs, the victim was apparently raised to a semi-upright position and held there while the pictures were taken from the head of the autopsy table. The purpose of these photographs was to document the scalp and upper back wounds, the exact location of which has been a matter of considerable controversy. In these photographs, the only facial features visible are the back of the ears.

In comparing these photographs with those taken in group 2, which show the right side of the head and face, several features common to both were noted. These include two dried blood stains on the upper right shoulder approximately 16 centimeters lateral to the midline of the back. Approximately 7 centimeters medial to these are a series of 3 narrow parallel marks approximately 3 centimeters in length.

which appear to be slight skin abrasions. These marks and stains are situated several centimeters lateral to the back wound and do not appear to be directly associated with it. It is possible that they were made in the course of the handling and lifting of the body.

There is also a 3- by 5-centimeter area of discoloration at the base of the neck in the right area which apparently represents either a slight contusion or some post mortem lividity. All of these features are very irregular in shape and would thus be very difficult if not impossible to duplicate. Such minor and random details are also the kind of characteristics that would likely be overlooked in any attempted hoax. Likewise, the hair, which is in disarray and matted with blood and body fluids, presents a complex of irregularly arranged strands and locks. Yet, allowing for the different angles of view, these features appear to be identical in size, location and shape in both the posterior (group 4) photographs and those of the right lateral photographs of group 1, which can be identified as being of President Kennedy.

In addition to the above rather transient feature, others of a more permanent nature were noted. These were the network of transverse wrinkles extending across the back and side of the neck. Such lines develop in most individuals by middle age, but their exact arrangement forms a pattern that is virtually unique to the individual. Examination of these in the back photographs of group 4 shows that they are identical in pattern and development (again making allowance for view) as those seen on the lateral side of the neck in the group 1 photographs. In short, the profusion of minute and common detail lend us to conclude that the individual shown in both sets of photographs is the same.

The photographs of group 5, which show the cranial cavity with the brain removed, are somewhat more difficult to evaluate. One feature of interest is the outline of the fractured margin of the frontal bone which is partially visible in the foreground of these photographs. A deep V-shaped irregularity in this margin is also visible in photographs of group 1 in which the scalp is partially reflected to expose the underlying bone. The anterior margin of the cranial defects also corresponds in shape to the fractures observed in the cranial X-rays.

From the standpoint of positive identification, the most problematic group of autopsy X-rays are those of group 6 which show the isolated brain. Here we could find no anatomical features that would associate this brain with the remaining autopsy photographs. However, the trauma to the brain, effecting primarily the superior aspect of the frontal lobes is certainly consistent with the pattern of cranial trauma observed in the autopsy photographs and X-rays.

#### CONCLUSION

Based on our examination of the autopsy X-rays and photographs and comparison of these with known ante mortem X-rays and photographs of John F. Kennedy, we conclude as follows:

1. The individual shown in the autopsy X-rays is John F. Kennedy.
2. The individual shown in the autopsy photographs is John F. Kennedy.

3. The brain shown in autopsy photographs Nos. 46 to 52 cannot be positively identified as that of John F. Kennedy. However, this brain displays trauma consistent to the known pattern of injury sustained by President Kennedy and, in the absence of any positive evidence to the contrary, there is no reason to believe that it is not the brain of the late President.

## REFERENCES

- (1) Wilbur, Charles C.: "Medicolegal Investigation of the President John F. Kennedy Murder," Charles C. Thomas, Springfield, Ill., 1978.
- (2) Humes, J. J., J. T. Boswell, J. H. Ebersole, and J. T. Stringer 1966. "Report of inspection by naval medical staff on Nov. 1, 1966, at National Archives of X-rays and photographs of autopsy of President John F. Kennedy."
- (3) Carnes, W. H., R. S. Fisher, R. H. Morgan, and A. Moritz 1968. "Panel review of photographs, X-ray films, documents and other evidence pertaining to the fatal wounding of President John F. Kennedy on Nov. 22, 1963, in Dallas, Tex." Washington, D.C.: National Archives.

TABLE I.—Description of autopsy photographs examined in authentication study

Number :		
26, head, right lateral.....	}	Superio-lateral view of head in quarter profile. Includes anterior neck wound, upper chest and shoulders.
27, head, right lateral.....		
28, head right lateral.....		
29, head left lateral.....	}	Profile view. Includes anterior neck wound. No. 30 over-exposed.
30, head, left lateral.....		
31, head, left lateral.....		
32, head, superior.....	}	Superior view of head and shoulders.
33, head, superior.....		
34, head superior.....		
35, head, superior.....		
36, head, superior.....		
37, head, superior.....		
38, upper torso, posterior.....	}	Shows shoulder wound.
39, upper torso, posterior.....		
40, head, right lateral.....	}	Inferio-lateral view of head in quarter profile. Includes anterior neck wound.
41, head, right lateral.....		
42, head, posterior.....	}	Close-up of occipito-partial area showing scalp wound.
43, head, posterior.....		
44, cranial cavity.....	}	Anterio-superior views of cranial cavity. Brain removed.
45, cranial cavity.....		
46, brain interior.....	}	Removed from cranial cavity.
47, brain, inferior.....		
48, brain, inferior.....		
49, brain, inferior.....		
50, brain, superior.....		
51, brain, superior.....		
52, brain, superior.....		

TABLE II.—Measurements used to derive indices for comparison of JFK ante mortem photographs with autopsy photograph No. 29

1. *Physiognomic face height*.—Distance from the midpoint of the hairline to the lowest point on the chin (trichion to menton).
2. *Forehead height*.—Distance from the midpoint of the hairline to the most anterior point on the lower forehead just above the nasal root depression (trichion to glabella).
3. *Nose length*.—Distance from the deepest point of the nasal root depression to the junction point between the nasal septum and the upper lip (subnasion to subnasale).
4. *Total face height*.—Distance between the most anterior point on the lower

forehead just above the nasal root depression and the lowest point on the chin (glabella to menton).

5. *Ear length*.—Distance between the uppermost point on the helix of the ear and the lowermost point on the earlobe (superaurale to subaurale).

6. *Lobe length*.—Distance between the lowest point in the intertragic notch and the lowest point of the earlobe (intertragon to subaurale).

7. *Chin height*.—Distance from the point of contact between the upper and lower lip and the lowest point on the chin (stomion to menton).

8. *Chin eminence height*.—Distance from the point of deepest depression between the lower lip and chin and the lowest point on the chin (supramentale to menton).

9. *Nasal projection*.—Distance from the most anterior point on the nasal tip to the junction point between the nasal septum and the upper lip (pronasale to subnasale).

10. *Nasal elevation*.—Distance from the most anterior point on the tip of the nose to the posterior most point on the junction line between nasal alae and the cheek (pronasale to postalare).

11. *Total facial depth*.—Distance between the most anterior point on the nasal tip and the posterior most point on the posterior margin of the helix of the ear (pronasale to postaurale).

TABLE III.—*Comparison of facial index values of ante mortem photographs of President John F. Kennedy (79-AR-6378G, 79-AR-8008K) with left profile photograph (No. 29) of autopsy subject*

Mean deviation=2.82

Index <sup>1</sup> (M/M x 100)	Antemortem			Post-mortem No. 29	Δ <sup>2</sup>
	79-AR- 6378G	79-AR- 8008K	Mean		
1. 2/1 x 100.....		27.0	27.0	30.7	3.7
2. 3/4 x 100.....	26.4	35.1	35.8	33.1	2.7
3. 8/4 x 100.....	21.4	21.1	21.2	18.1	3.1
4. 7/1 x 100.....		28.4	28.4	25.6	2.8
5. 7/4 x 100.....	37.1	36.8	37.0	33.8	3.2
6. 6/5 x 100.....	29.4	33.9	31.6	33.9	2.3
7. 5/1 x 100.....		41.2	41.2	37.5	3.7
8. 9/3 x 100.....	47.1	45.0	46.0	50.0	4.0
9. 10/3 x 100.....	60.8	61.5	61.2	63.6	2.4
10. 5/11 x 100.....	49.7	45.9	47.8	47.5	.3

<sup>1</sup> Numbers refer to measurements defined in table II.

<sup>2</sup> Absolute differences between mean of ante mortem index and post mortem index.

TABLE IV.—*Morphological similarities in both the ante mortem and post mortem Kennedy photographs*

Convex angle of nasal septum.  
 Lower third of nose convexity.  
 Nasal tip area elevated.  
 Attached ear lobe.  
 Strong ear antihelix.  
 "Tucked" ear tragus.  
 Distinctive lip profile.  
 Identical facial crease lines.  
 Similar neck crease lines.



## (181) ADDENDUM B

### REPORT TO THE SELECT COMMITTEE ON ASSASSINATIONS, U.S. HOUSE OF REPRESENTATIVES

#### IDENTIFICATION OF THE SKULL X-RAY FILMS TAKEN DURING THE AUTOPSY OF PRESIDENT JOHN F. KENNEDY

(By Lowell J. Levine, D.D.S., Consultant for the Select Committee  
on Assassinations, U.S. House of Representatives, Sept. 7, 1978)

#### AUTHENTICATION OF AUTOPSY FILMS 1, 2, AND 3

##### BASIS FOR DENTAL IDENTIFICATION

The science of dental identification is based upon the fact that characteristics associated with the dentition and the hard and soft tissue structures of the oral cavity occur in astronomical numbers of combinations.

Typically, the adult dentition contains 16 teeth in each jaw; 4 incisors, 2 canines, 4 premolars, and 6 molars. Each tooth has characteristics such as morphology, root configuration, root canal shapes, anomalies, pathology, and the like which are unique and individual to that particular tooth. Similarly, the supporting structures of the oral cavity have unique and individual characteristics.

Teeth are often attached by carious lesions (decay) and other processes which cause unique and individual characteristics.

There are five surfaces on each tooth which may be attacked by dental caries and restored by the dentist. On posterior teeth (premolars and molars), mesial and distal (toward and away from the midline), occlusal (the grinding surface), buccal (towards the cheek), and lingual (towards the tongue). On anterior teeth (incisors and canines) mesial and distal, facial or labial (towards the face or lips), lingual, and incisal (cutting surface). These surfaces may be attacked by dental caries singly or in combination and restored by the dentist in single- or multiple-surface restorations. Different surfaces on the same tooth may be restored with various filling, insulating, and lining materials. Different sized and shaped dental burs (drills) are used to remove the dental caries, and prepare the tooth to receive the filling material.

The dentist uses various materials to repair the effects of dental caries. Metals such as gold in various forms and silver amalgam are commonly used. Porcelains and acrylics are used and various cements are used as temporary restorations, insulating materials, and sealers.

It should be abundantly clear that the possible combinations which may occur because of such factors as presence or absence of particular teeth, surfaces of each tooth free of caries or decayed, surfaces of each tooth present restored with various types of dental materials, sizes and shapes of cavity preparations is limitless.

Almost all dental evidence is useful for identification purposes. Dental evidence could include the written records of examinations and treatments. Models of the mouth, teeth, and jaws used for diagnosis and treatment planning or the actual fabrication of prosthetic appliances. The prosthetic appliances themselves. Photographs and X-ray films taken incident to diagnosis and/or treatment.

X-ray films are excellent evidence for identification purposes. The films will graphically exhibit characteristics such as presence or absence of teeth, rotations of teeth, level of eruption of teeth, tipping of teeth, and the relation of these teeth to each other.

The films will show the morphology of teeth, roots, and root canals as well as the presence of caries, root canal therapy, pathology such as retained roots and cysts, unerupted teeth, anomalies, wear, and breakage among other things.

We may examine the shapes of fillings, extent of caries involvement and removal, cement materials present, and density of filling materials. Hard tissue patterns, pathology, and landmarks are also graphically represented.

Even when extensive dental treatment, performed subsequent to the date of the X-ray films, has considerably altered the visual appearance of the teeth, the underlying hard tissue characteristics remain quite distinctive.

#### DENTAL IDENTIFICATION PROCESS

The dental identification process will include a comparison by the forensic odontologist of the unique and individual characteristics exhibited by the evidence at hand with previously existing records containing evidence of those same characteristics. The forensic odontologist will use his training, experience, skill, and expertise to form an opinion as to whether his comparison is positive. He will render that opinion in a report which will also contain the basis for that opinion.

The early use of dental identification in the United States can be documented in two historically significant cases which both occurred in President Kennedy's home State of Massachusetts.\*

Paul Revere, noted for his famous ride and as a silversmith, also practiced dentistry. Gen. Joseph Warren, a Revolutionary War hero killed at the Battle of Bunker Hill, had been a patient of Revere. Originally buried by the British, his remains were subsequently identified by Revere some 10 months later when Revere recognized a prosthetic appliance he had made for General Warren.

In 1850 the Webster-Parkman case shocked Boston. Dr. John White Webster, professor of chemistry and mineralogy at Harvard Medical School was convicted of murdering Dr. George Parkman, professor of anatomy at Harvard Medical School. In his first recorded instance of dental identification in the courtroom, Dr. Nathan Cooley Keep, subsequently first dean of Harvard Dental School, identified a few fragments of lower jaw and an intact porcelain bridge which fitted the cast Dr. Keep had preserved from recent dental care of the

---

\*Historical references: Sognaes, Reider F., "Talking Teeth", *American Scientist*, vol. 64, p. 369 Luntz & Luntz, "Handbook for Dental Identification," J. B. Lippincott, Philadelphia, 1973, pp. 1-15.

missing Dr. Parkman. An expert witness for the defense was William Morton, the young Boston dentist of ether anesthesia fame.

#### EVIDENCE USED IN THE DENTAL IDENTIFICATION PROCESS

The evidence to be used for the comparisons was in the custody of the National Archives of the United States at the time I examined it. There was a "descriptive list" of the materials which was apparently made when the National Archives received them from the Kennedy Library.

"Descriptive list" (items I personally used for comparisons):

1. *Manila envelope—business letter size.*—Addressed to Capt. J. W. Pepper, D.C., USN, containing two dental films, loose JFK July 12, 1962.
2. *Manila envelope—business letter size.*—marked JFK April 4, 1962, containing two dental films, loose.
3. *Manila envelope—about 5 by 6 inches.*—
  - a. One mounted dental film dated March 11, 1961.
  - b. Two mounted dental films dated March 11, 1961.
  - c. Five mounted dental films dated January 18, 1961.
  - d. One mounted dental film dated March 8, 1962.
6. *Manila Sleeve, about 10 inches by 12 inches.*—JFK sinus films, August 17, 1960, containing five films.
7. *Manila envelope (sic), about 10 inches by 12 inches.*—JFK sinus films, August 14, 1960, containing four films.

Description of 1, 2, 3, 6, 7:\*

1. *Two dental films loose.*—Both are left mandibular periapical\*\* type films. The root apices (ends of the roots) do not appear on the films. One film is taken slightly anterior to the other. The anterior film includes a portion of the lower left canine, both lower left premolars, the lower left first molar, and a portion of the lower left second molar. (Universal Nos. 22, 21, 20, 19, 18.)

The posterior film includes a portion of the lower left first premolar, the lower left second premolar, the lower left first molar, and a portion of the lower left second molar. (Universal Nos. 21, 20, 19, 18.)

The following surfaces are interpreted to be restored: first premolar (No. 21), distal occlusal; second premolar (No. 20), mesial occlusal distal; first molar (No. 19), mesial occlusal distal; second molar (No. 18), mesial occlusal.

The restorations are interpreted as cast metal restorations. A less radio opaque material pulpal (toward the "nerve") to the restorations is interpreted as dental cement. The lower left first molar (No. 19) appears to have a portion of a previous metallic restoration on the pulpal floor.

2. *Two dental films loose.*—Both are left mandibular periapical type films. One film includes the root apices, the other does not. Both films

\*The teeth will be described by name and by the universal numbering system. In this system the maxillary (upper) right third molar is No. 1, the maxillary left third molar No. 16, the mandibular (lower) left third molar No. 17, the mandibular right third molar No. 32.

\*\*This type film usually is of the crown and root portions of a tooth or teeth in a segment of one jaw.

include a portion of the lower left canine, the two lower left premolars, the lower left first molar, and a portion of the lower left second molar. (Universal Nos. 22, 21, 20, 19, 18.)

The following surfaces are interpreted to be restored: first premolar (No. 21), distal occlusal; second premolar (No. 20), mesial occlusal distal; first molar (No. 19), mesial occlusal distal; second molar (No. 18), mesial occlusal.

The restorations are interpreted as cast metal restorations. A less radio opaque material pulpal to the restoration is interpreted as dental cement. The lower left first molar (No. 19) appears to have a portion of a previous metallic restoration on the pulpal floor.

3a. *One mounted dental film dated March 11, 1961.*—A film mount marked, "Kennedy JF March 11, 1961," contains a left bite wing\* type film. It includes a portion of the upper left first premolar, lower left first premolar, upper and lower second premolars, first and second molars. (Universal Nos. 12, 13, 14, 15, 21, 20, 19, 18.)

The following surfaces are interpreted to be restored:

Upper: First premolar (No. 12), mesial occlusal distal; second premolar (No. 13), mesial occlusal distal; first molar (No. 14), mesial occlusal distal; second molar (No. 15), mesial occlusal distal.

Lower: First premolar (No. 21), distal occlusal; second premolar (No. 20), mesial occlusal distal; first molar (No. 19), mesial occlusal distal; second molar (No. 18), mesial occlusal.

The restorations are interpreted as cast metal on all surfaces except for those of the two upper premolars. The restored surfaces on these two teeth are metallic and may be either cast metal or silver amalgam. There is dental cement pulpally on all teeth except the upper and lower first premolars. There appears to be a portion of a previous metallic restoration on the pulpal floor of the lower left first molar.

3b. *Two mounted dental films dated March 11, 1961.*—A film mount marked, "Kennedy John F 11 March 61" contains two maxillary left periapical type films. These include a portion of the upper first premolar, upper second premolar, upper first molar, and upper second molar. (Universal Nos. 12, 13, 14, 15.)

The following surfaces are interpreted to be restored: First premolar (12), distal occlusal (mesial portion of tooth is not shown on the film); second premolar (13), mesial occlusal distal; first molar (14), mesial occlusal distal (probably lingual); second molar (15), mesial occlusal distal.

All restorations are interpreted as being of metal with the molars probably cast metal. There is cement visible under all restorations with the exception of the first premolar.

3c. *Five mounted dental films dated January 18, 1961.*—A film mount marked, "Kennedy, Pres John F January 18, 1961". The mount bears a stamp, "Robert D. Morris, D.D.S., 140 East 54th St., New York, 22, N.Y."\*\* The mount contains five X-ray films. There are two right bite

\*This type film is usually of the crown portions of opposing teeth of a segment or an entire side.

\*\*Dr. Morris confirmed the fact that he treated President Kennedy on Jan. 18, 1961 in a telephone conversation which occurred on June 7, 1978. This appointment was 2 days prior to his inauguration. He had a routine "check up" which included X-rays and "cleaning".

wing type films, two left bite wing type films, and one maxillary left periapical type film.

One right bite wing film is taken anterior to the other. The more anterior film contains a portion of the upper and a portion of the lower canine, the upper and lower first and second premolars, the upper and lower first molars, a portion of the upper and lower second molars. The more posterior film contains a portion of the upper and a portion of the lower second premolars, the upper and lower first and second molars.

The following surfaces are interpreted to be restored:

Upper right: Canine (6), distal; first premolar (5), occlusal; second premolar (4), mesial occlusal distal; first molar (3), mesial occlusal distal; second molar (2), mesial occlusal.

Lower right: First premolar (28), occlusal, occlusal; second premolar (29), distal occlusal; first molar (30), mesial occlusal distal; second molar (31), mesial occlusal.

The upper right canine is interpreted as having a cement restoration. All other restorations are metal. The first premolars appear to have silver amalgam restorations, all others appear to be cast metal. There appears to be cement pulpal to all restorations except those of the first premolars.

One left bite wing film is taken anterior to the other. Both films include the upper and lower first premolars, second premolars, first molars and second molars. The more anterior film includes a portion of the upper and lower second molars, the more posterior film, a small portion of the upper and lower first premolars.

The following surfaces are interpreted to be restored:

Upper left: First premolar (12), distal occlusal; second premolar (13), mesial occlusal distal.

Upper left: First molar (14), mesial occlusal distal; second molar (15), mesial occlusal distal.

Lower left: First premolar (21), distal occlusal; second premolar (20), mesial occlusal distal; first molar (19), mesial occlusal distal; second molar (18), mesial occlusal.

The restorations are interpreted as cast metal on all surfaces with the exception of the two upper premolars. The restored surfaces on these two teeth are metallic and may be either cast metal or silver amalgam. There is dental cement pulpally on all teeth except the upper and lower first premolars. There appears to be a portion of a previous metallic restoration on the pulpal floor of the lower first molar.

The maxillary left periapical film includes a portion of the upper first premolar, second premolar, first and second molars.

The following surfaces are interpreted to be restored:

Upper left: First premolar (12), distal occlusal; second premolar (13), mesial occlusal distal; first molar (14), mesial occlusal distal (probably lingual); second molar (15), mesial occlusal.

The restored surfaces of the molars are interpreted as cast metal. The premolars may be either cast metal or silver amalgam. There appears to be cement under all restorations with the exception of the first premolar.

3d. *One mounted dental film dated March 8, 1962.*—A film mount marked, "JF Kennedy March 8, 1962" contains an upper left periapi-

cal-type film. The film concludes a portion of the upper left canine, first and second premolars, first molar, and a portion of the second molar.

The following surfaces are interpreted to be restored :

Upper left: First premolar (12), distal occlusal; second premolar (13), mesial occlusal distal; first molar (14), mesial occlusal distal; second molar (15), mesial occlusal (the distal portion of) No. 15 is not in the film.

All surfaces are restored in metal. The molars appear to be restored with cast metal the premolars with either cast metal or silver amalgam. Cement is apparent pulpally on all teeth but the first premolar.

6. *JFK sinus films, August 17, 1960, \* \* \* five films.*—There is a container marked, "5 sinus films"—J.F.K.

It is labeled: "Name Kennedy, Mr. John F., No. 336042; Remarks August 17, 1960.

Drs. Groover, Christie & Merritt  
1835 I Street NW.  
Washington 6, D.C."

The manila sleeve contains five X-ray films. One is a lateral skull film. Four are AP films taken at various angulations.

The configuration of the frontal sinuses can be clearly determined from the AP films.

The following dental restorations can be interpreted from the lateral skull film:

Upper left: First premolar (12), distal occlusal; second premolar (13), mesial occlusal distal; first molar (14), mesial occlusal distal; second molar (15), mesial occlusal distal.

Lower left: First molar (19), mesial occlusal distal; second molar (18), mesial occlusal.

Superimposition in the premolar area makes clear interpretation difficult. Overlapping makes clear interpretation difficult toward the anterior region.

These restorations all appear to be metallic. Cement can be clearly seen pulpal to the restorations in the molar area. There appears to be a portion of a previous metallic restoration pulpal to the restoration and cement liner on the lower left first molar (19).

7. *JFK Sinus Films, August 14, 1960, \* \* \* four films.*—There is a container marked, "#202617, 8-14-60, JFK, Dr. Stephen White, 'Sinus X-Rays'".

The envelope contains one lateral skull film and three AP-type films taken at various angulations.

The configuration of the frontal sinus can be clearly determined from the AP films.

The following dental restorations can be interpreted from the lateral skull film: Upper right second molar (2), occlusal portion of restoration; upper left second molar (15), distal portion of restoration; lower right first molar (30), mesial occlusal distal; lower right second molar (31), mesial occlusal.

There is considerable superimposition and overlap.

*Authenticity of 1, 2, 3a, 3b, 3c, 3d, 6, 7.*

The first task of the forensic odontologist is to form an opinion as to whether the films he will use for comparison with the films in ques-

tion are authentic. The 22 films described were received by the National Archives from the Kennedy Library. According to a source at the Kennedy Library, the films were found in the White House after the death of the President. They came to the Kennedy Library through a family member.\*

Dates of Films and Source :

August 14, 1960—later skull film ; three AP skull films—Dr. Stephen White, No. 7.

August 17, 1960—lateral skull film, four AP skull films—Drs. Groover, Christie, & Merritt No. 6.

January 18, 1961—five dental films—Dr. Robert D. Morris—No. 3c two right bite wings, two left bite wings, one left maxillary periapical.

March 11, 1961—three dental films—Capt. J. W. Pepper, D.C., USN—No. 3a, 3b; one left bite wing, two left maxillary periapicals.

March 8, 1962—one dental film—Capt. J. W. Pepper, D.C., USN—No. 3d; one left maxillary periapical.

April 9, 1962—two dental films—Capt. J. W. Pepper, D.C., USN—No. 2; two left mandibular periapicals.

July 12, 1962—two dental films—Capt. J. W. Pepper, D.C., USN—No. 1; two left mandibular periapicals.

Films of the left side :

No. 1. Two films July 12, 1962—two mandibular periapicals.

No. 2. Two films April 9, 1962—two mandibular periapicals.

No. 3a. One film March 11, 1961—bite wing.

No. 3b. Two films March 11, 1961—two maxillary periapicals.

No. 3c. Three films January 18, 1961—two bite wings, one maxillary periapical.

No. 3d. One film March 8, 1962—maxillary periapical.

No. 6. One film August 17, 1960—lateral skull.

There are 12 films taken over a 23 month period by at least three different sources, Drs. Pepper, Morris, and White.

Films of the right side :

No. 3c. Two films Jan. 18, 1961—two bite wings.

No. 7. One film Aug. 14, 1960—lateral skull (also shows portion of left).

There are three films taken in a 5-month period by two different sources, Dr. Morris and Drs. Groover, Christie, and Merritt.

There are seven films useful for comparing frontal sinus configurations, No. 6 and No. 7 from two different sources, Dr. White and Drs. Groover, Christie, and Merritt.\*\*

*Opinion as to the authenticity of the films to be used for comparisons*

Dr. Robert D. Morris confirms the fact that he did expose X-ray films on President John F. Kennedy on Jan. 18, 1961. There are numerous unique and individual characteristics reproduced in the 15 films illustrating the dentition. The films were acquired from at least four different sources. Films taken in like areas may be easily

\* William Moss, chief archivist, Kennedy Library.

\*\*It is interesting to note that President Kennedy had numerous X-ray films of the left side taken in the period between Mar. 11, 1961 and July 12, 1962. One could speculate that he was suffering from some nonspecific dental pain of the left posterior area during that period.

compared with each other. It is my opinion that all films were taken on the same person, John F. Kennedy.

*Autopsy films 1, 2, 3*

Description of films:

1. AP skull film.
2. Lateral skull film.
3. Lateral skull film.

Each film is marked, "21296" U.S. Naval Hospital, NNMC, Bethesda, Md.

*Description of areas of comparison of autopsy 1, 2, 3*

*Autopsy 1.*—The configuration of the frontal sinuses are quite distinctive. The right side is "heart" shaped, the left almost "rhomboid."

*Autopsy 2.*—There is considerable superimposition and overlap of the jaws, teeth, and restorations, however, the right side appears slightly superior. There is a radio-opaque rectangular-shaped object with three small and one large radiolucent circular areas in it extending from the second lower premolar considerably beyond the third molar area. It obliterates the roots of the molars and extends at an angle beyond the inferior border of the mandible. Because of the angulation at which this film was taken, this object is parallelogram shaped, the circular areas oval-shaped.

The configuration and juxtapositions of a number of the dental restorations are useful for comparison purposes. The two occlusal restorations can be clearly interpreted on the lower right first premolar (28) as can the occlusal portion of the distal occlusal restoration on the lower right second premolar (29). In the second molar area the two second molars are superimposed upon each other. The very distinctively shaped cement liner in the lower left second molar (18) is quite apparent. It is kidney-shaped with the concavity toward the pulpal floor. The deeper portion extends toward the distal. Immediately above the cement liner is the occlusal portion of the mesial occlusal restoration. The concave distal occlusal wall is apparent. The shallow portion of the distal occlusal wall of the mesial occlusal restoration in the lower right second molar (31) can be interpreted immediately above the convexity of the distal occlusal wall of the lower left second molar (18) restoration. The deeply rounded floor of the mesial portion of the mesial occlusal restoration on the lower left second molar (18) can be seen.

The distal portions of restorations on the upper second molars can be interpreted although considerably superimposed upon each other.

There are unquestionably ample unique and individual characteristics which can be interpreted for comparison purposes contained in this film.

*Autopsy 3.*—There is no superimposition of the maxillary left segment. Although there is slight overlap, the configuration and juxtapositions of the dental restorations in this segment can be readily interpreted. There is superimposition of the right maxillary molar area on the superior portion of the occlusal of the lower right second premolar (29) and lower right first molar (30). There is a radio-opaque rectangular object, apparently the same object as in autopsy 2, which obliterates almost entirely both lower left premolars, the roots of the



lower left first molar, and a portion of the roots of the lower left second molar. The lower left second molar appears free of distortions.

The characteristics of the restorations and existing lining materials can be readily interpreted on the following teeth: Upper left: First premolar (12); second premolar (13); first molar (14); second molar (15).

Upper right: First premolar (5); second premolar (4).

Lower left: First molar (19); second molar (180).

There are numerous unique and individual characteristics which can be interpreted for comparison purposes contained in this film.

### *Comparisons*

*Autopsy 1.*—The configurations and relationships of the frontal sinuses depicted in this film and in films contained in sinus 6 and sinus 7 are similar.

*Autopsy 2.*—The unique and individual characteristics described in this film can also be interpreted in films contained in: 1, 2, 3a, 3c, 6, and 7.

*Autopsy 3.*—The unique and individual characteristics described in this film can also be interpreted in films contained in: 1, 2, 3a, 3b, 3c, 3d, 6, and 7.

### *Conclusions*

It is my opinion that autopsy films 1, 2, and 3 are unquestionably of the skull of President John F. Kennedy. It is further my opinion that the unique and individual dental and hard tissue characteristics which may be interpreted from autopsy films 1, 2, and 3 could not be simulated.

LOWELL J. LEVINE, D.D.S.

### EXHIBITS

Comparison of dental X-rays are visually quite persuasive when presented to juries of lay persons as photographic "blowups". The forensic odontologist can easily demonstrate the characteristics and relationships he has interpreted to form his opinion.

Almost at the outset of my examination in consultations between Dr. Michael M. Baden, the committee staff, and myself, it was decided it would be very desirable to attempt to get permission to reproduce portions of X-ray films which were significant in forming my opinion.

The strongest reason for publishing facsimiles of the X-ray evidence is that they are so much more convincing than a narrative description of characteristics compared.

The committee staff obtained permission for me to photograph and reproduce portions of the films I felt were necessary to document the identification and authentication. Autopsy No. 1, was not photographed at that time because it was my understanding that my permission precluded reproducing areas which depicted injury pattern. The fact that documentation of autopsy No. 1, is not included in these exhibits should in no way be construed to imply that my opinion as to the authenticity of that film is anything less than a positive identification.

On November 15, 1977, I personally photographed the films at the National Archives. The exhibits were produced under my direction

by Walter Poppe, forensic photographer, office of the medical examiner, Nassau County, N.Y., while employed as a private consultant.

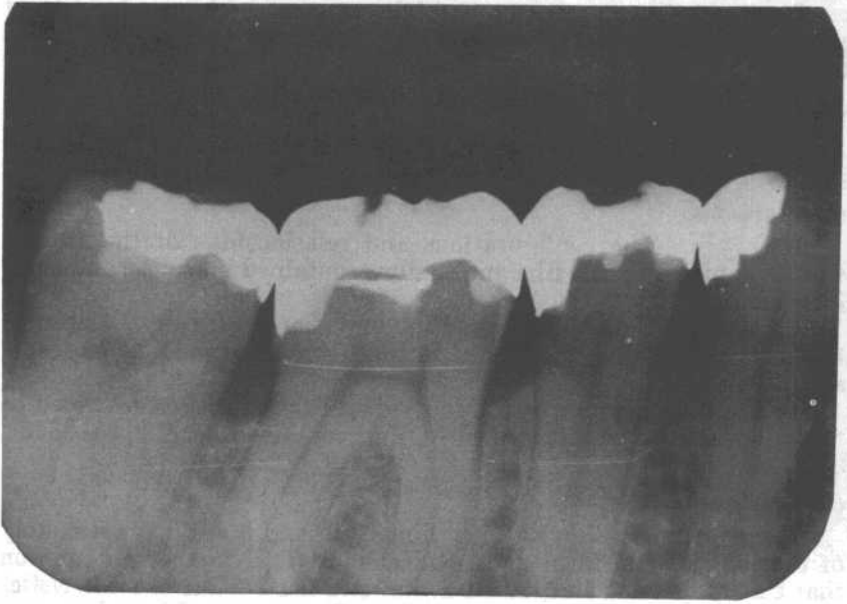


FIGURE 1.—Dental film (descriptive list 1) taken July 12, 1962. The more posterior of the two films described.

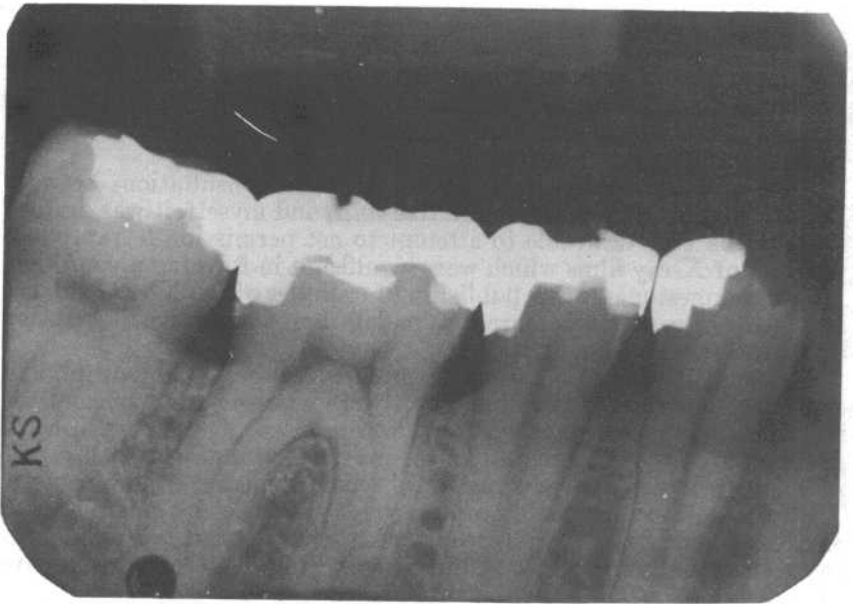


FIGURE 2.—Dental film (descriptive list 2) taken April 9, 1962. One of the two films described.

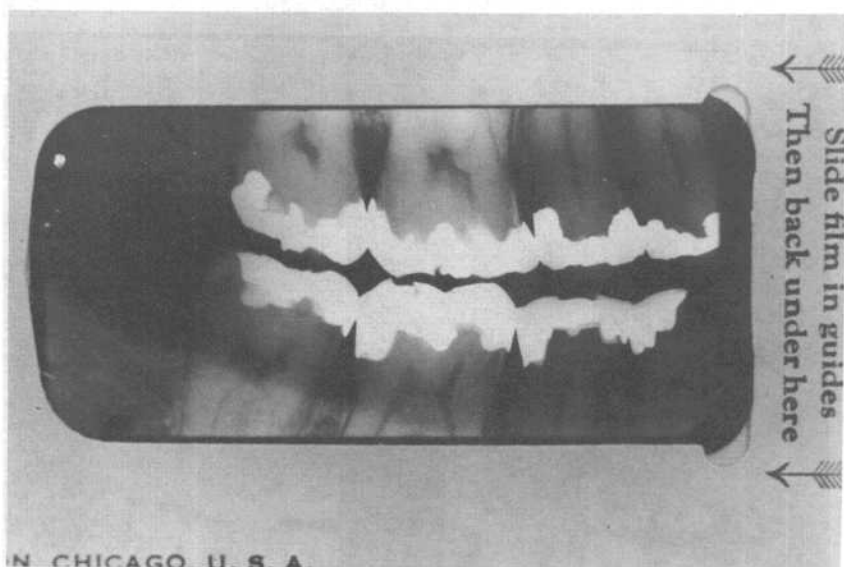


FIGURE 3.—Dental film (descriptive list 3a) taken Mar. 11, 1961.

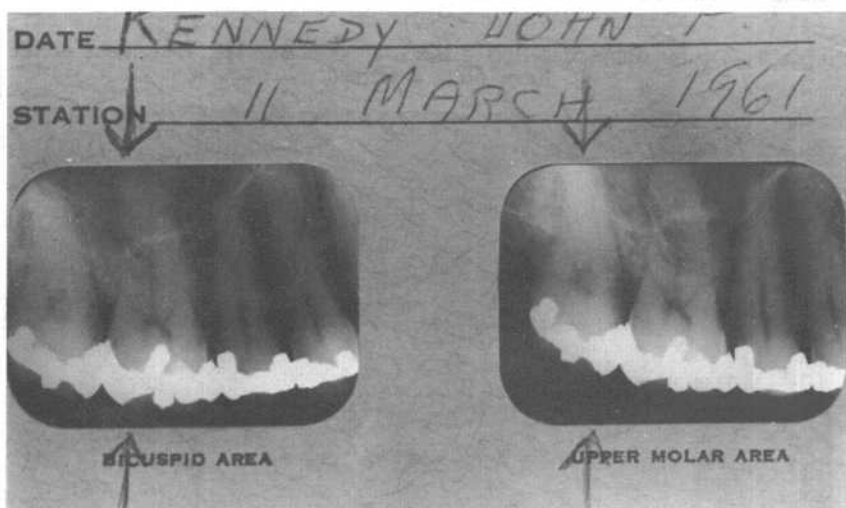


FIGURE 4.—Dental films (descriptive list 3b) taken Mar. 11, 1961.

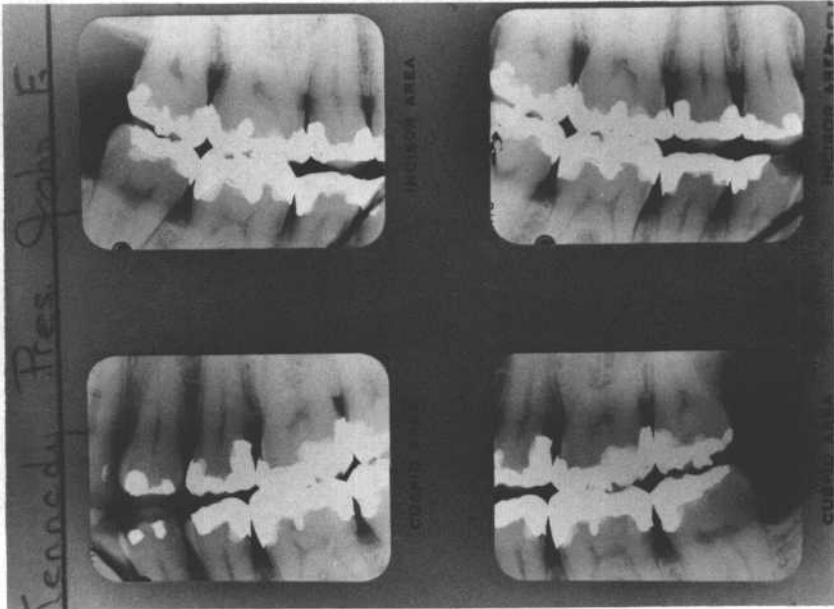


FIGURE 5.—Dental films (descriptive list 3c) taken Jan. 18, 1961. Four of the five films described.

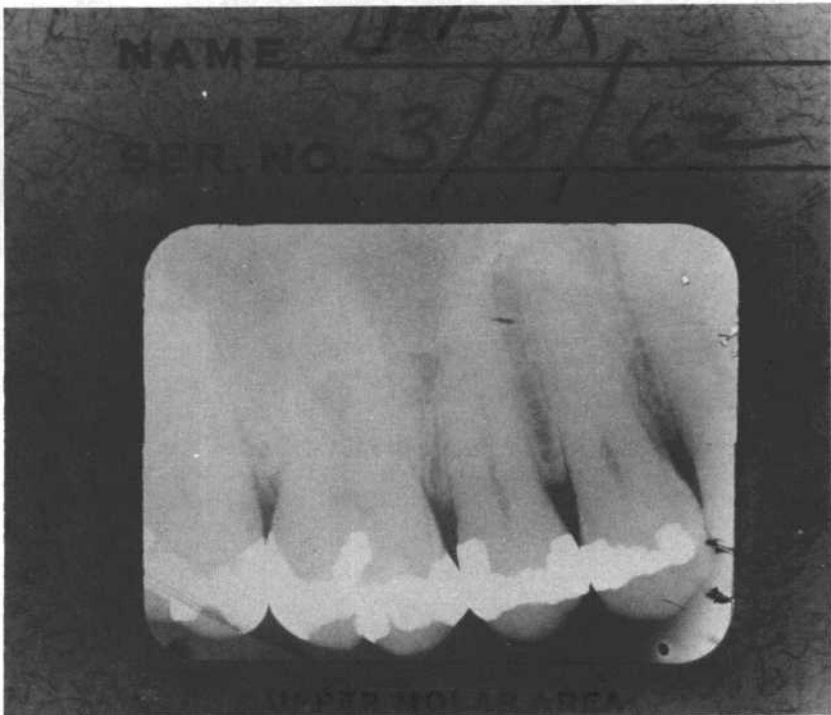


FIGURE 6.—Dental film (descriptive list 3d) taken Mar. 8, 1962.

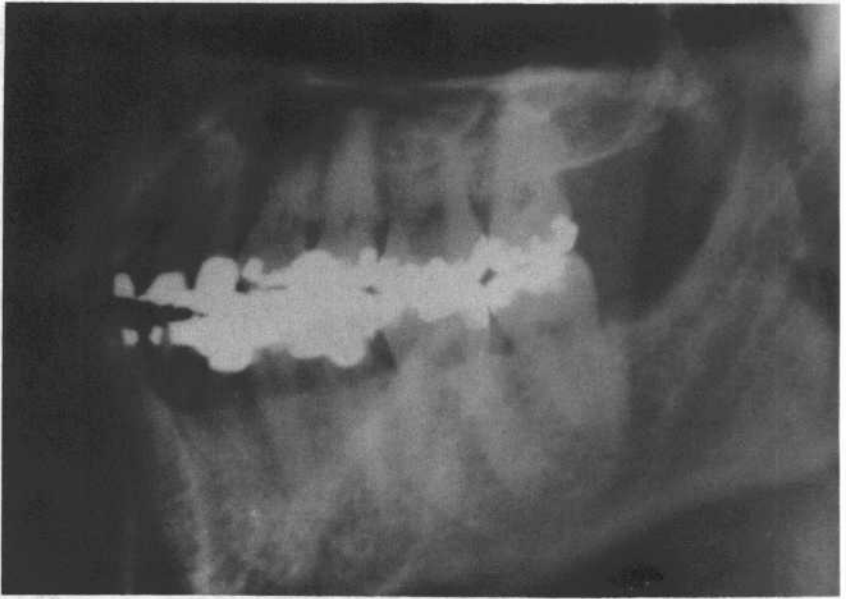


FIGURE 7.—Sinus film (descriptive list 6) taken Aug. 17, 1960. Dentition and supporting structures depicted in lateral skull film.

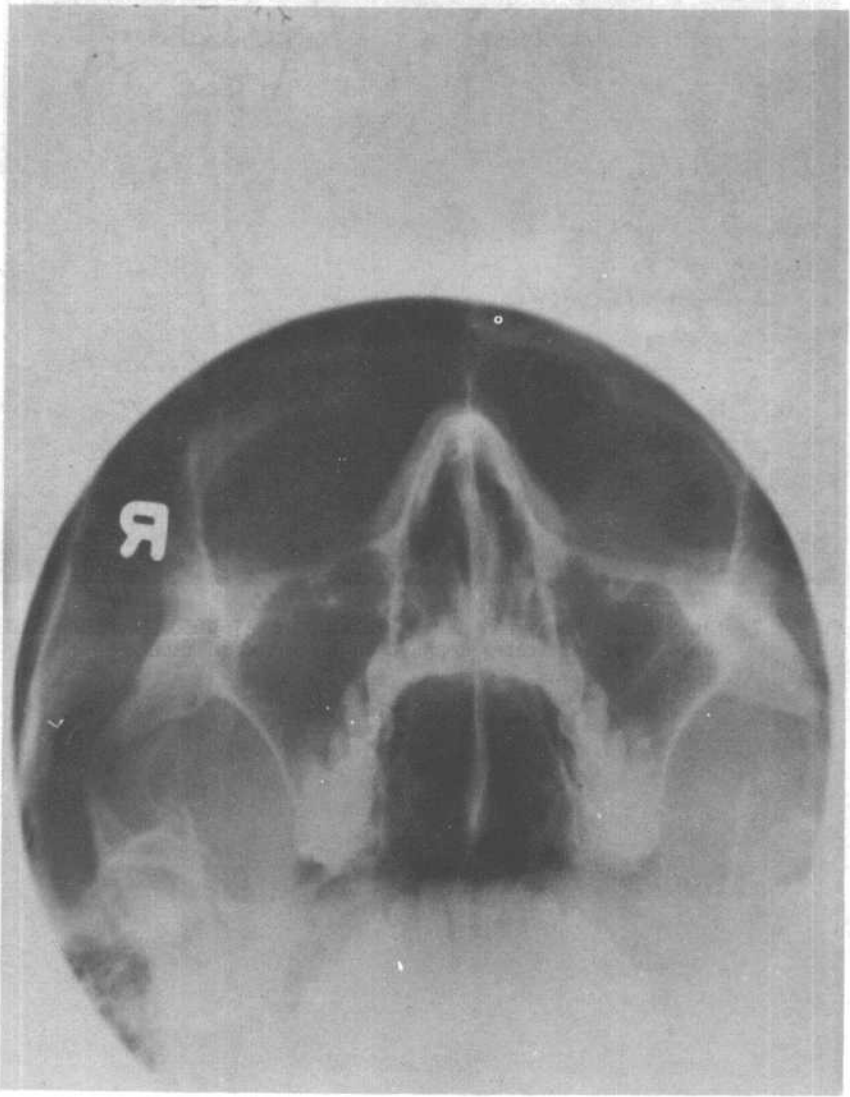


FIGURE 8.—Sinus film (descriptive list 6) taken Aug. 17, 1960. "Waters Position" type film.

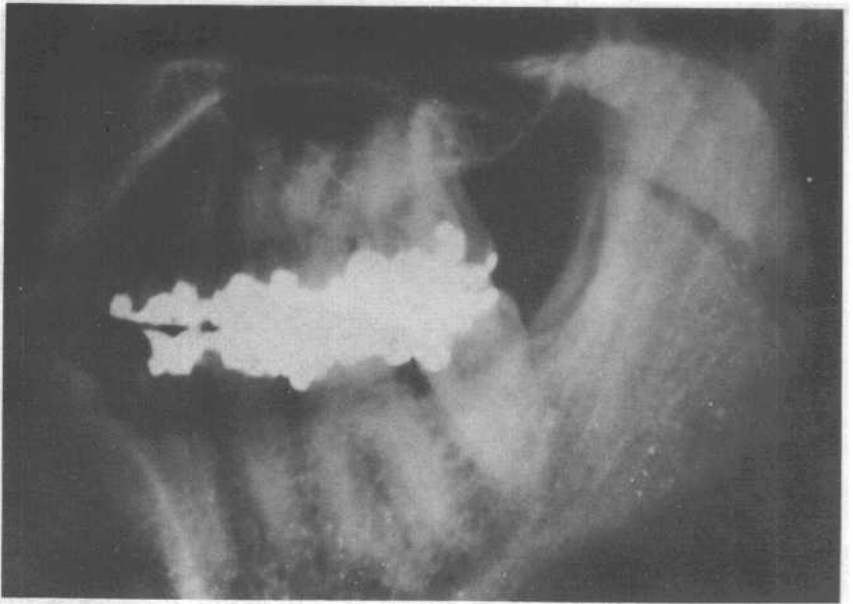


FIGURE 9.—Sinus film (descriptive list 7) taken Aug. 14, 1960. Dentition and supporting structures depicted in lateral skull film.

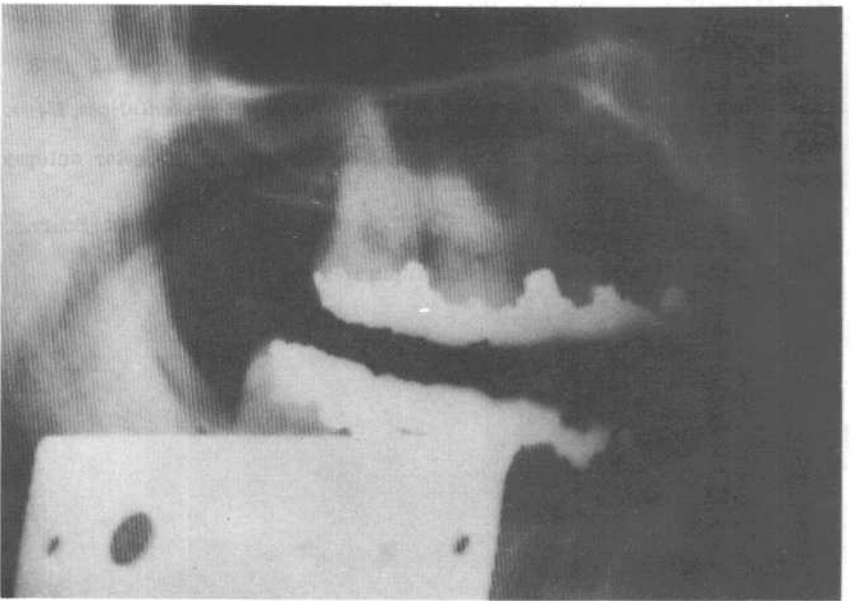


FIGURE 10.—Autopsy 2. Dentition and supporting structures.

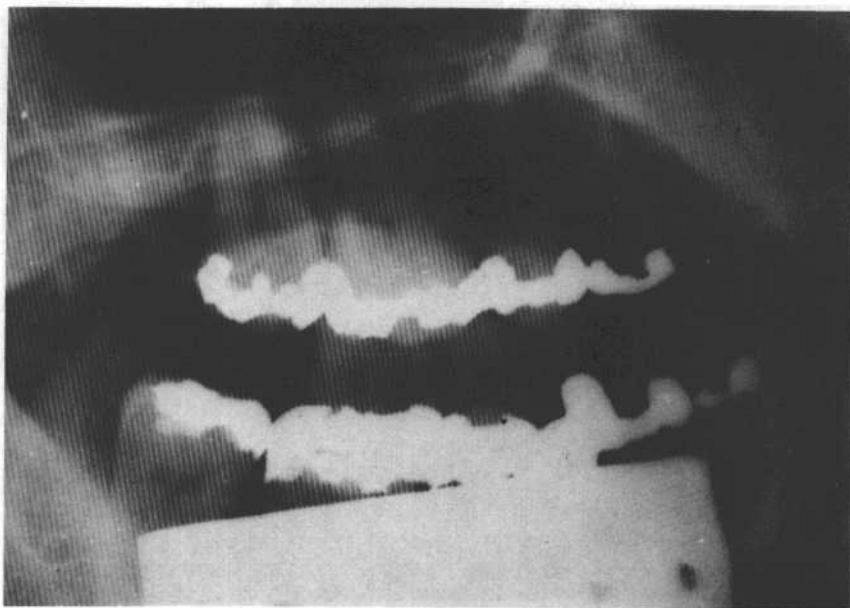


FIGURE 11.—Autopsy 3. Dentition and supporting structures.

\*(182) ADDENDUM C

WEST REDDING, CONN., *August 15, 1978.*

Ms. JANE DOWNEY,  
*House Select Committee on Assassinations, U.S. House of Representatives, House  
 Office Building, Annex 2, Washington, D.C.*

DEAR JANE: Enclosed is a report on the authenticity of the color autopsy pictures.

With best regards,

FRANK SCOTT.

---

\*Paragraphs (183) to (190) represent duplicated material.



## REPORT ON AUTOPSY COLOR PHOTOGRAPHS AUTHENTICITY

(By Frank Scott, August 15, 1978)

I have carefully analyzed the original color transparencies exposed in the camera used by the photographer during the autopsy of President Kennedy. The photographer took two or more pictures of each scene; for each scene he used a different exposure (different shutter speed or different lens f-number) for each of the two or more pictures; this is a common practice of photographers to enhance the probability that one of the pictures of a particular scene is exposed properly and also as insurance in the event any of the two or more pictures of a scene are lost due to camera or processing (developing) failures.\* The two or more pictures taken by the photographer of a particular scene in several instances were made with the camera in slightly (a few centimeters) different positions in space. For other scenes, the photographer made the two or more exposures from the same position in space, probably using a tripod on which the camera was mounted or using a specimen stand as was, apparently, the case for the pictures made of the brain specimen. The fact that two or more pictures of a particular scene were made from slightly different positions is very fortunate because the variation in camera position provides true stereophotography, somewhat analogous to the different positions of microphones in stereo recording of an orchestra. A pair of stereo pictures enables one to see the scene in three dimensions; stereo pictures add depth to the perception of the photographed scene in much the same way as a pair of human eyes, separated from one another in space, can perceive depth.

The stereo pairs of pictures provide a sound basis upon which to assess the authenticity of the photographs. The same is true of the non-stereo pairs, such as the brain pictures, but to somewhat lesser extent.

In the case of nonstereo pairs of pictures, the pictures can be superimposed on one another; the superimposition can be achieved physically (actually placing one transparency over or on another transparency) or by optical means (where the image of the transparencies are optically brought together in register). Careful examination of the superimposed pictures will reveal differences between the two pictures. In viewing stereo pairs of photographs, one eye views one picture and the other eye views the second picture; the eyes, coupled with the visual image processes of the brain, very readily reveal differences be-

---

\* I was employed as a medical photographer at the M. D. Anderson Hospital and Tumor Research Institute while attending college; for the photography of patients, for autopsy photography, and for anatomical specimen photography it was a policy of the photography department to take three pictures of every scene photographed for the reasons cited above; after film processing the two poorest pictures were discarded.

tween the two pictures. When viewing a photographed scene using a stereo pair of photographs, differences in the scene between the two pictures tend to "pop out at you", that is, are easily noted. When viewing a photographed scene using a nonstereo pair of photographs, differences between the photographs are apparent but not as readily noted and thus require more careful examination.

To successfully avoid detection of picture alteration requires that each picture of a pair of pictures be altered identically, which is essentially impossible, particularly with a stereo pair since each picture of a stereo pair is a picture of the scene from a slightly, but directly comparable, point of view. Any nonidentical alteration of the pictures of a pair is readily noted when pairs are viewed stereoscopically or monoscopically. A clear demonstration of this is provided by one particular stereo pair: In one picture of the pair there are more droplets of blood on the towel directly beneath a clump of hairs of President Kennedy's head than there are in the other picture of the pair; when viewing this scene in stereo, it becomes very quickly and clearly apparent that the two pictures are not identical with specific respect to this blood-droplets detail; obviously, during the elapsed time between the two pictures, additional blood dripped from the hair onto the towel.

In a careful examination of the pictures made of each scene, and in searching for, and finding, candidate pictures for stereo pairs for use by medical experts for the select committee, I did not find any indication or evidence that any of the pictures were altered and, thus, I conclude that these pictures are authentic photographs. In forming this conclusion, I assume that the object photographed is, indeed, the body of President Kennedy.

Attachment.

#### TRANSPARENCY IDENTIFICATION NUMBERS

Among the autopsy transparencies, the following pairs provided stereoscopic viewing of the photographed scene:

43 JB and 42 JB  
 33 JB and 32 JB  
 44 JB and 45 JB  
 34 J7B and 37 J7B  
 26 J7B and 28 J7B

while the following pairs provided stereoscopic viewing but of poor stereo quality:

38 JB and 39 JB  
 41 J7B and 40 J7B

while the following pairs, or sets of three pictures, appeared to be identical to one another but did not provide stereoscopic viewing:

32 JB and 36 JB  
 37 JB and 35 J7B  
 29 J7B and 31 JB and 30 J7B  
 26 J7B and 27 J7B  
 47 JB and 46 JB and 48 JB  
 52 J7B and 51 JB and 50 JB

The numbers refer to those appearing on the envelopes or protective cellophane sleeves of the 4 by 5 inch positive transparencies as provided

to me by Archive Courier, Mr. Bill Grover, on March 2, 1978; these numbers may not be consistent with other references to these photographs during the past years since the transparencies may not have been stored consistently in their own, correct, envelope or sleeve; the "JB" or "J7B" portion of the notations or labels may not be correct since it is merely my interpretation of letters/numbers which were not clearly written and possibly misread by me.

